High Ankle Sprains… A guest blog by Tom Whittamore – The Sports Physio

From: www.thesports.physio

CONSIGNAS

1- RECONOCE SI LAS FRASES VERBALES RESALTADAS EN AMARILLO SON ACTIVAS O PASIVAS. ESCRIBE FRASE VERBAL ACTIVA – FRASE VERBAL PASIVA.

2- IDENTIFICA A QUE TIEMPO VERBAL PERTENECEN. COMPLETA CON:

- PRESENTE SIMPLE
- PASADO SIMPLE
- PRESENTE CONTINUO
- PRESENTE PERFECTO
- FUTURO
- VERBO MODAL

You *have probably noticed* that the last few blogs on 'The Sports Physio' have been either deep and meaningful or a little bit controversial. So I thought it was high time to get back to what we *do* best and get a clinically relevant and meaningful blog out there for you all. So I am *pleased* to introduce to you all young Tom Whittamore who is an Academy Physio for Derby FC. Tom *has done* a very thorough and enjoyable blog on ankle syndesmosis injuries, more commonly known as, and rather flippantly called high ankle sprains… they ain't just sprains. Tom *is soon undertaking* his MSc and has an interest in hammies and of course ankle injuries… so over to you Tom!

Welcome to my first ever blog and many thanks for Adam for *agreeing* to host it for me. I *decided* to write this having recently rehabilitated an ankle syndesmosis injury so I wanted to look into this area a bit more. The aim of this blog is to look at what the syndesmosis is, how it *is injured*, what tools we have to diagnose the 'high ankle sprain', and how I undertook a recent rehabilitation of this injury.

Introduction

The ATFL is the most commonly injured ligament in the ankle, and an injury to the syndesmosis can account for around 10% of all ankle injuries, as reported by Boytim et al (1991) who studied professional (American) football players in a six year study and found syndesmostic sprains *accounted* for 18 out of 98 ankle injuries reported. Hermans et al (2010) *estimated* that between 1-11% of all ankle injuries *involved* the syndesmosis.

Anatomy

The distal tibiofibula joint is an articulation of the convex surface of the fibula, and the concave tibia (Norkus and Floyd, 2001). It *is stabilised* by the syndesmosis which contains the interosseus membrane which runs all the way between the tibia and fibula, and three other ligaments which provide stability at the distal end of the joint. The ligaments are the anteroinferior tibiofibula ligament, the posteroinferior tibiofibula ligament, a transverse ligament, and the previously mentioned interosseous membrane (Williams and Allen, 2010).

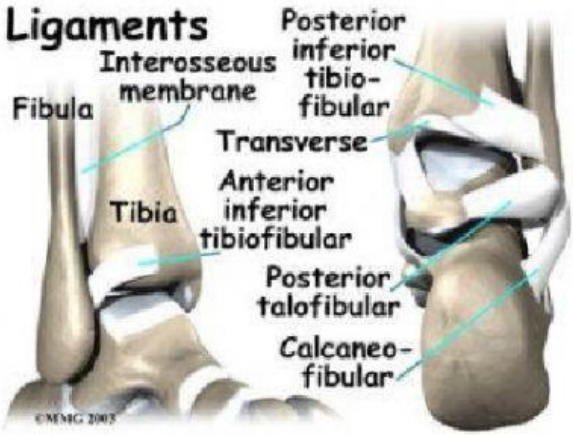

morphopedics.wikidot.com

Ogilvie-Harris et al (1994) *completed* a cadaver study *investigating* the amount of stability provided by these ligaments at the distal tibiofibula joint.

They *demonstrated* that the AITFL accounts for 35% of the joints stability, the interosseus membrane 22% whilst the PITFL provides around 42%. Therefore we *can see* that an injury to one or more of these ligaments can cause a significant amount of instability within the joint.

Mechanism

An injury to the tibiofibula joint *can be caused* by contact or non contact. This could be in a tackle where a player's foot is in contact with the ground and forcibly externally rotated, or when a player suddenly changes direction with the foot *planted* and moving into external rotation.

It *has been shown* that dorsiflexion and external rotation causes *increased* tension to the ligaments at the distal tibiofibula joint. This mechanism causes the talus to rotate and as a result can cause separation between the tibia and fibula stressing the ligaments, or worst case scenario, *causing* a rupture (Norkus and Floyd, 2001)

The external rotation mechanism has been shown to initially affect the AITFL; further rotation would then pose a risk to the interosseus membrane and PITFL (Hermans et

al, 2010; Hunt, 2013). The normal gap between the tibia and fibula is around 5mm (Hunt, 2013); but even an extra 1mm increase in joint space can cause instability in the ankle.

Diagnosis

Following a suspected syndesmosis injury, it is important to gather appropriate information from the subjective assessment such as: mechanism, *swelling*, location of pain etc.

Objectively a suspected syndesmosis injury *may have* pain and swelling over the distal tibiofibula joint, reduced range of movement and strength, difficultly weight bearing (or inability to be able to push off). It is important to consider other structures in the ankle such as the deltoid ligament, which has been shown to be injured in conjunction with the syndesmosis complex, due to its accessory role in stabilisation of the distal tibiofibula joint (Hunt, 2013).

The common test I use to test for a syndesmosis injury is the external rotation test. This *can be done* in sitting or (if the player can weight bear) in standing (replicating the mechanism of injury). In sitting the player is sat over the edge of the bed, the knee is stablised and the foot moved into dorsiflexion and eversion. Pain *would point* towards a suspected syndesmosis sprain (Williams and Allen, 2010).

In a systematic review, Schwieterman et al (2013) looked at the diagnostic accuracy of special tests at the foot and ankle, their results (which didn't include Pakarinen, I have just added it to the table) are below:

Test	Sensitivity	Specificity	Paper	Subjects
Cotton Test	0.25 0.25	N/A 0.98	Beumer et al Pakarinen	28 288

External Rotation	0.99 0.20 0.58	N/A 0.85 0.90	Beumer et al De Cesar et al Pakarinen	294 56 288
Fibula Translation	0.75	0.88	Beumer et al	322
Squeeze Test	0.30	0.94	De Cesar et al	56

The squeeze test involves the therapist *compressing* the middle lower leg; any pain in the syndesmosis region is considered a positive test for a syndesmosis injury. I have never used this test for a syndesmosis injury, some clinicians I *have worked* with do use it, and others do not. I prefer the external rotation test which is enough for me to suspect a syndesmosis injury.

The fibula translation test has been found to have the highest sensitivity and specificity but I have never come across this in practice and I am unaware of anyone else who uses this.

Finally once the syndesmosis *is suspected*, the injured party should be referred on for an MRI Scan to confirm the diagnosis. This method has a 96% accuracy of predicting injury to the syndesmosis compared to 63% when sent for an x-ray (Takao et al, 2003; Oae et al, 2003). A stress x ray may also show a syndesmosis injury, although Parakinen *suggested* that the poor sensitivity found *will limit* its effectiveness despite having a high specificity.

Surgery or Conservative?

One of the main factors in *deciding* whether to operate or manage conservatively will be the amount of instability present and the severity of the structures injured following a syndesmosis injury.

Conservative management typically will take six to eight weeks for the injury to heal, however there is a possibility that the injury will not have recovered sufficiently leaving

patients with a degree of instability and a chance of reinjury. This would leave the player/patient likely to be needing surgery in the future. Instability was found by Hermans et al (2010) in 40% of all ankle sprains with patients reporting symptoms of instability six months later. This shows the importance of *resolving* the instability to limit complications later on which could have a significant impact on function.

Currently the surgical technique for syndesmosis injuries involves tightrope fixation to help stabilise the joint, and depending on recovery it can take around ten to twelve weeks for a player to return to *training*.

The Tightrope

The tightrope fixation is aimed at stabilisating the syndesmosis to reduce the instability at the distal tibiofibula joint. This is completed by threading a wire through the tibia and fibula and is then held in place by two suture buttons. The benefit of this procedure is that it reduces the need for any further surgery where screws were previously needed to be removed following an internal fixation; screws are still used but only if there is evidence of a fracture in the area. As always there is an element of complication, this can include a numb patch over and around the operation site, soft tissue irritation where the tightrope buttons are placed, or in more severe and rare cases as highlighted by Storey et al (2012) osteomyelitis over the implant.

http://si-instability.com/surgery-rt-leg-proximal-distal-tib-fib-joint-syndesmosis-arthrex-

Rehabilitation

Following surgery the general guidance is for six weeks healing time before beginning the main rehabilitation process. For the first two weeks the player is immobilised non weight bearing in a backslab, then moved into an aircast boot for the remaining four weeks during which time they can begin partial weight bearing as tolerated with the aim of being full weight bearing by the end of the six weeks. Particular notice should be paid towards avoiding dorsiflexion and eversion during this time to reduce the risk of applying unnecessary tension to the joint and tightrope.

Being immobilised for a prolonged period of time is likely to lead to ankle joint stiffness, muscle shortening (particularly the gastroc-soleus complex) and a loss of muscle bulk in the upper and lower leg.

0-6 weeks

The player was given exercises for his glutes and core, all of which was completed non weight bearing. Glute work consisted of long and short lever exercises whilst the core incorporated exercises such as dead bugs and supermans. Further to this, the strength

and *conditioning* coach provided a programme so that the player could work on his upper body strength.

To increase muscle bulks I used an electrical stimulating device called Compex. This device stimulates the muscles and causes them to contract which the player has to resist against. It is not the most comfortable piece of equipment to use (which I can confirm after being a guinea pig). Until the player was able to do leg weights then the compex is their friend, completing an alternating pattern of quadriceps/hamstrings. The player started off on a small compex session of 32 reps (effectively 4 sets of 8 reps) and then built up from there.

Six weeks +

Once the six weeks was over then we began to step up the rehabilitation. This meant we could start to incorporate leg weights (once swelling was controlled) and begin ankle specific exercises which included calf raises, ankle theraband work and proprioception drills

Another program on the compex device was called ankle twist prevention (not a fan of the word prevention, I believe reduction is a more appropriate word) helped build up the strength of the peroneals to further help with the stability around the ankle.

Having been immobilised for six weeks there was a considerable amount of ankle stiffness contributed by tight muscles and stiff joints. To help reduce this we worked on mobilising the ankle as well as trying to increase muscle length. I found the talocrural and distal tibia-fibula joints very stiff so some time was spent working to alleviate this. To help increase the player's movement we also used a continuous passive motion

(CPM) machine working on plantarflexion, dorsiflexion, inversion and eversion which the player completed daily up until full range of movement (ROM) had been restored.

Mobilising the joints around the ankle including the talocrural, subtalar, superior and distal tibiofbula joints helped alleviate some of the ankle stiffness. Stretches including proprioceptive neuromuscular facilitation (PNF) helped reduce tone in the muscles. Obtaining dorsiflexion was one of the key outcomes to achieve which would help reduce the risk of further complications such as posterior ankle impingement.

We utilised a different number of surfaces to work on the player's proprioception:

A stable surface such as grass/artificial grass/hard floor to incorporate tandem walking, heel toe walks, different ball drills such as volleys, two touch and headers. Other surfaces included foldable mats stacked up on top of one another to create an unstable environment, an airtrak mat, bosu and foam cushion, and semi circular rolls. Due to the reduced proprioceptive awareness we started off by allowing the player to focus on where they were walking during the activity. To make this more difficult for the player, a ball was placed under their chin so that the player was unable to look at where their foot was being placed, in essence making it harder to balance.

When balance, strength and ROM had improved, the player began work on landing techniques, this started off with basic two legged landing, two leg to one leg, one leg to two leg, over hurdles, forwards and backwards. Once the player developed confidence in their ability it was made a bit more football specific for example, going up for a header but having an opponent (in this case, me) try and challenge them so that they experienced football specific scenarios.