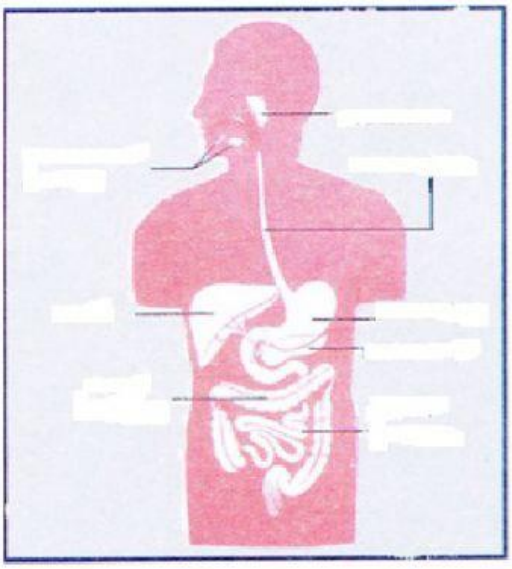

Εικ. 5.1 Το πεπτικό σύστημα

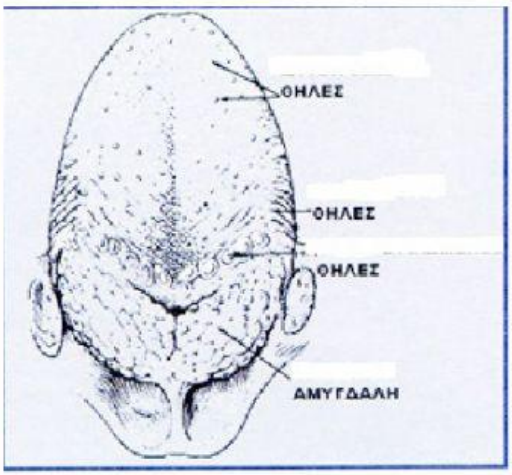

Εικ. 5.3 Οι θηλές της γλώσσας

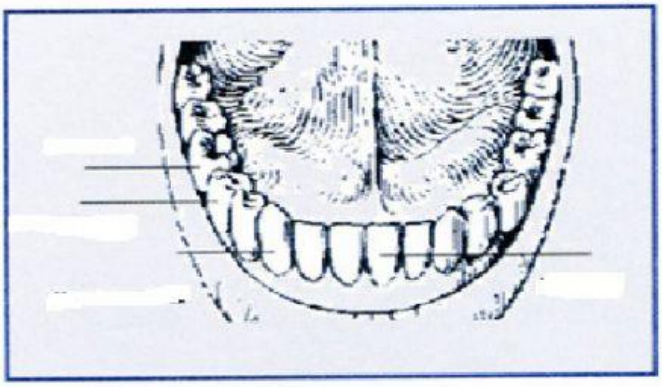

Εικ. 5.4 Τα δόντια

LIVEWORKSHEETS

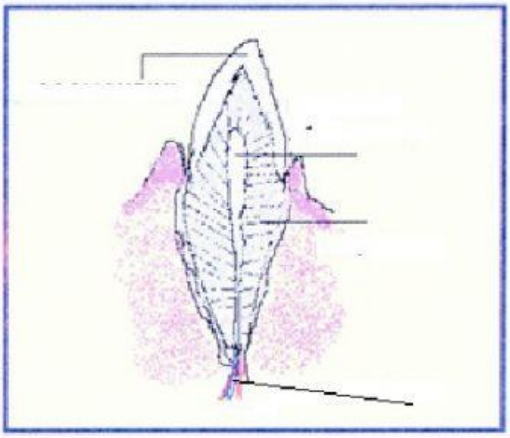

Εικ. 5.5 Η κατασκευή των δοντιών

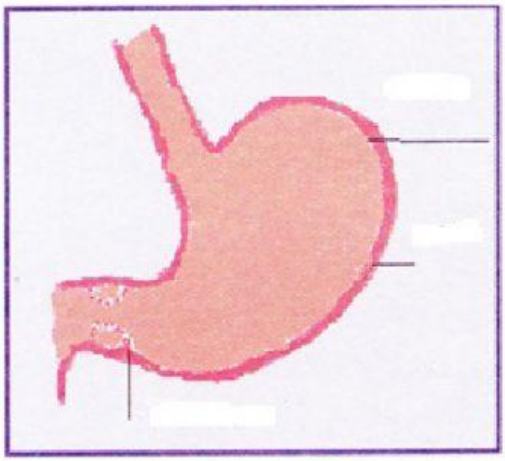

Εικ. 5.7 Το στομάχι

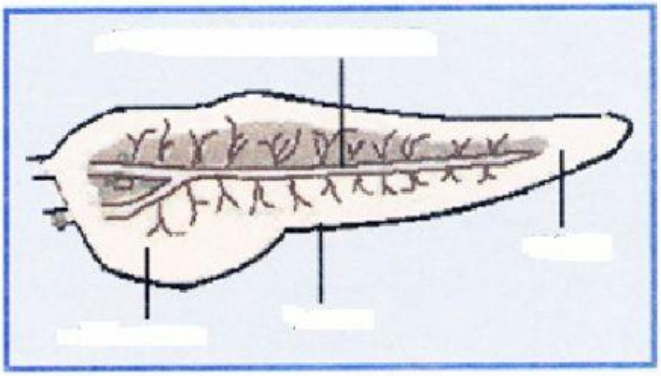

Εικ. 5.12 Το πάγκρεας

LIVEWORKSHEETS

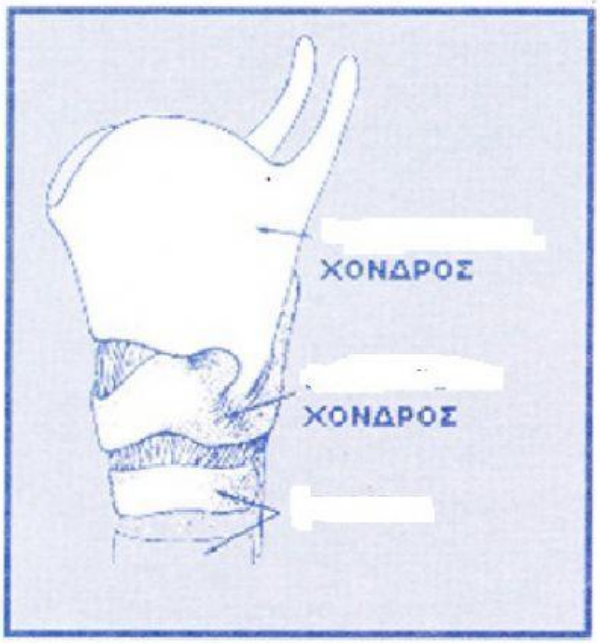

Εικ. 6.3. Ο λάρυγγας

LIVEWORKSHEETS

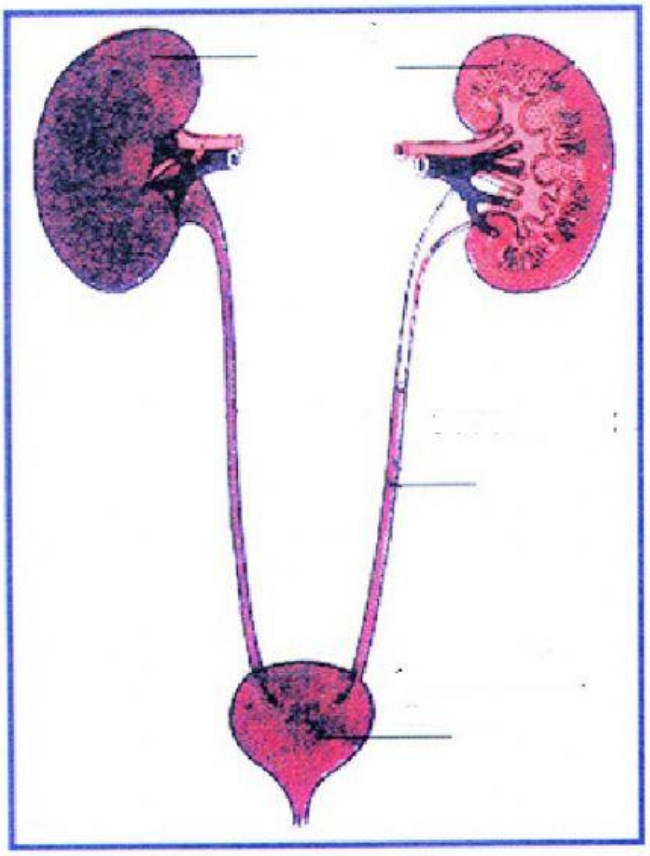

Εικ. 7.1 Το ουροποιητικό σύστημα

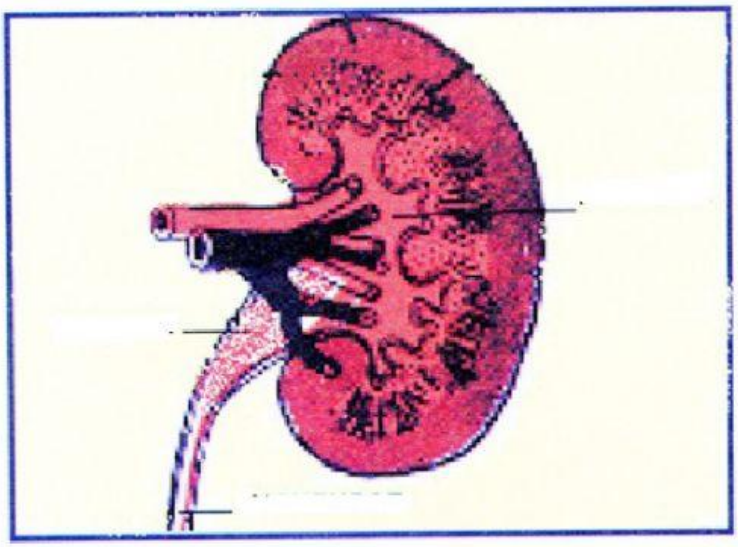

Εικ. 7.2 Ο νεφρός

LIVEWORKSHEETS

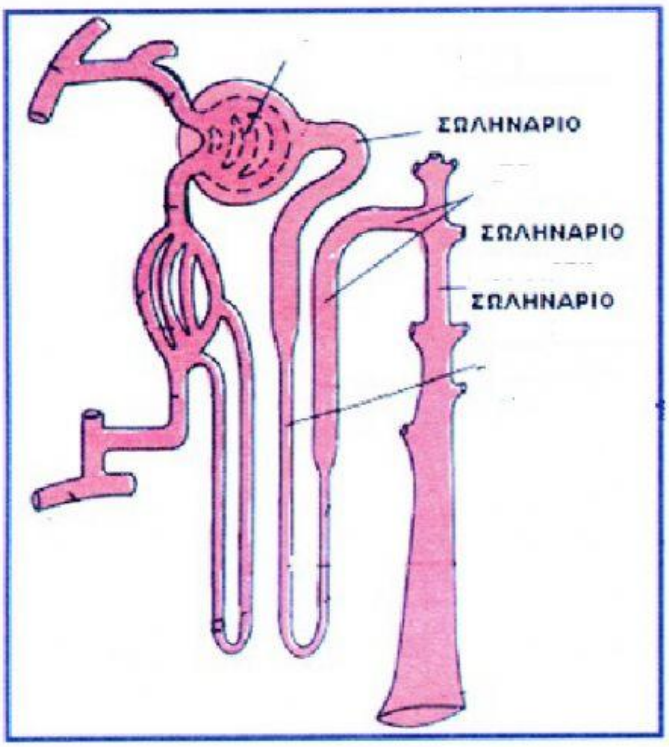

Εικ. 7.3 Ο νεφρώνας

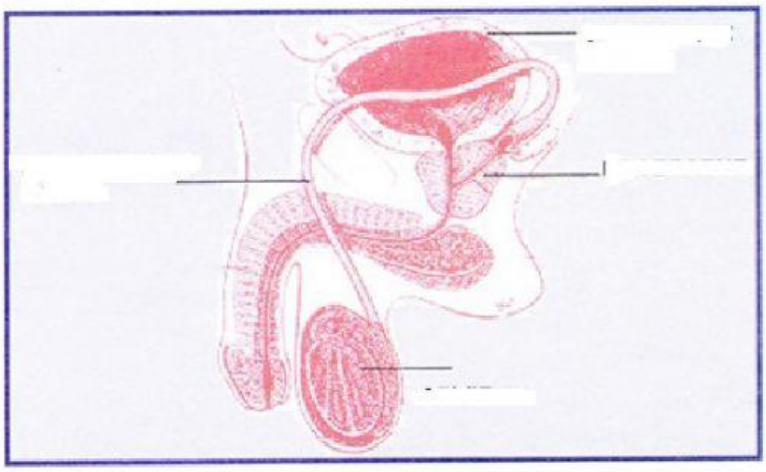

Εικ. 8.1 Το γεννητικό σύστημα του άνδρα

LIVEWORKSHEETS

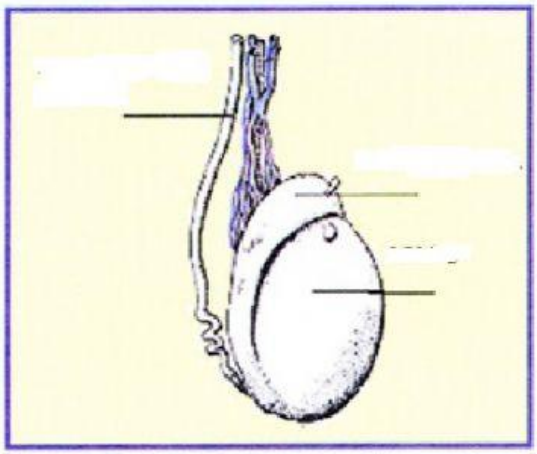

Εικ. 8.2 Ο όρχις

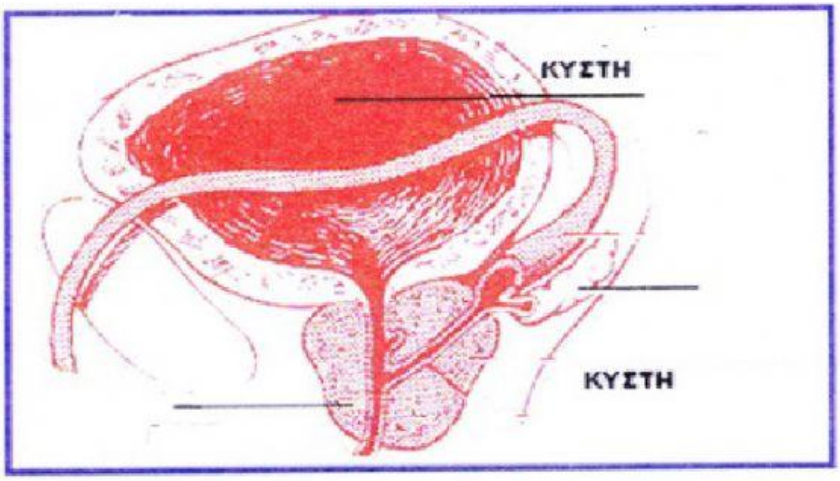

Εικ.8.3 Ο προστάτης αδένας και η σπερματοδόχος κύστη

LIVEWORKSHEETS



Εικ. 8.4 Το σπερματοζωάριο



Εικ. 8.5 Το γεννητικό σύστημα της γυναίκας

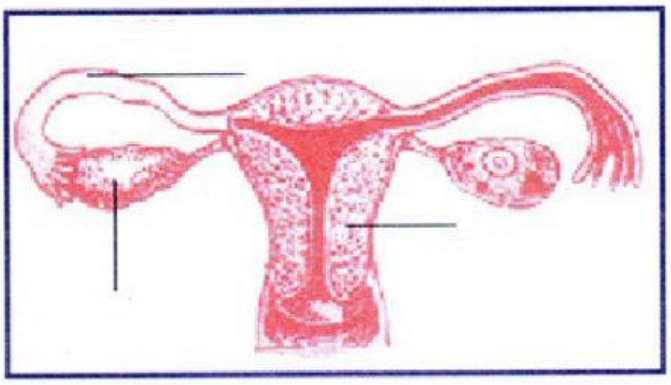

Εικ.8.6 Τα έσω γεννητικά όργανα της γυναίκας

LIVEWORKSHEETS

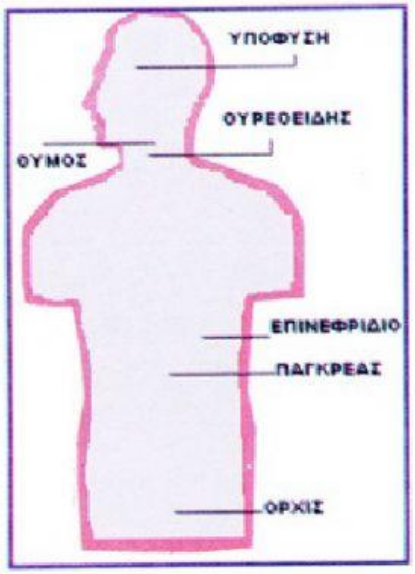

Εικ. 9.1 Το ορμονικό σύστημα

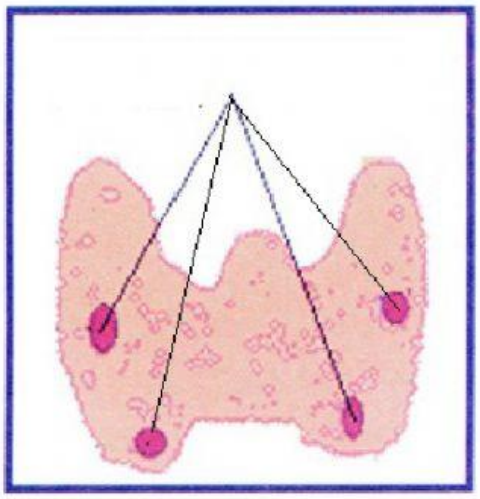

Εικ. 9.2 Ο θυρεοειδής αδένας και οι παραθυρεοειδείς αδένες

LIVEWORKSHEETS