

LET'S TALK ABOUT TEETH!

The tooth consists of two anatomical parts: the **CROWN** and the **ROOT**.

The _____ of a tooth is the part **inside* the gum***; it is normally **not visible**.

The _____ is the part of a tooth that is normally **visible** in the mouth.

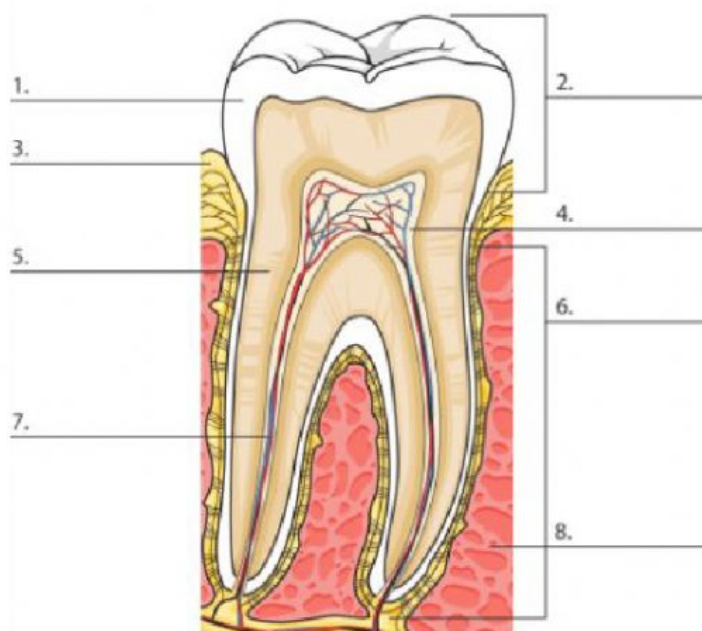
STRUCTURE OF A TOOTH

Match nouns and definitions using colours.

ENAMEL	It is the layer below* the enamel .
PULP*	It is the part of a tooth normally visible in the mouth.
CROWN	It is the whitish* covering* of the crown. It is the hardest substance in the body.
DENTIN*	It is the soft portion inside the dentin . It consists of blood vessels* and nerves.
ROOT	It is the part inside the gum .

Label the picture using the words from the box.

dentin - pulp - root - gums - crown - blood vessels and nerves - enamel - jawbone*



* inside = dentro

pulp= polpa

dentin = dentina

gum = gengiva

whitish = biancastra

vessels = vasi sanguigni

enamel = smalto

covering = copertura

jawbone = mandibola

below = al di sotto