# Skeletal System

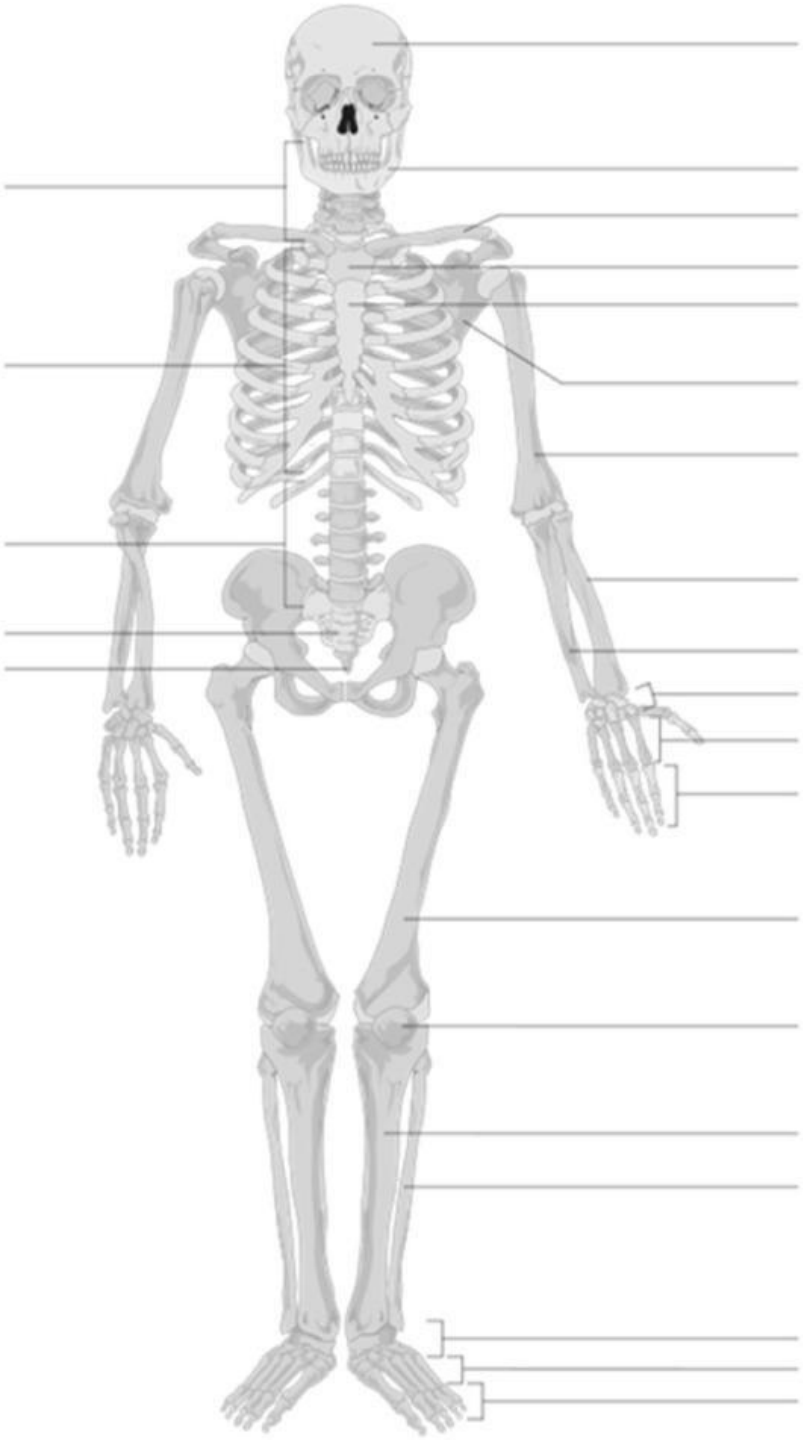

coccyx, scapula, metatarsals, cranium, radius, carpals, sternum, fibula, ribs, humerus, thoracic vertebrae, pelvic girdle, mandible, sacrum, lumbar vertebrae, ulna, phalanges (use twice), femur, manubrium, clavicle, cervical vertebrae, metacarpals, tarsals, patella, tibia

LIVEWORKSHEETS