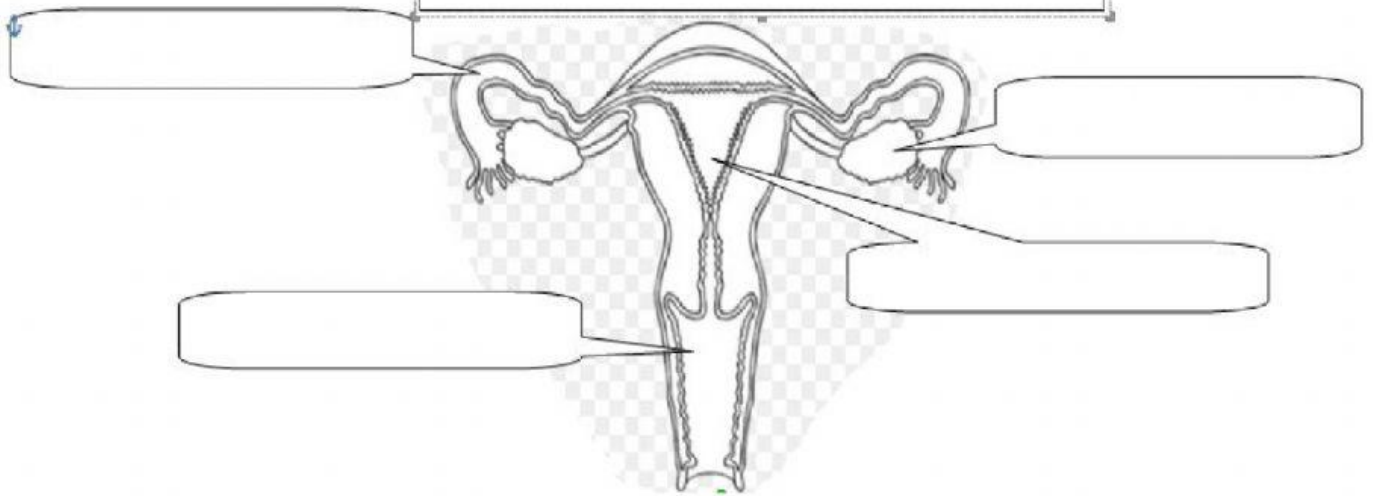
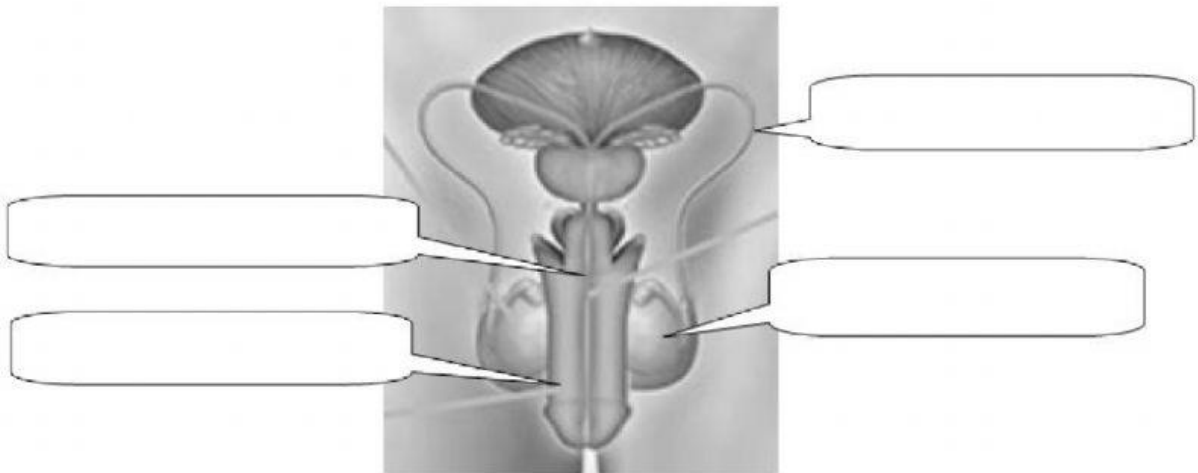


FEMALE REPRODUCTIVE SYSTEM



VAGINA	UTERUS
FALLOPIAN TUBES	OVARIES

MALE REPRODUCTIVE SYSTEM



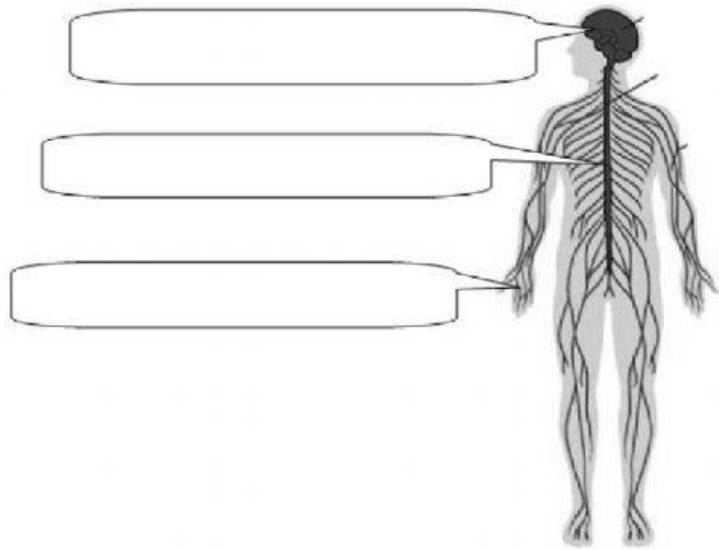
TESTICLES

VAS DEFERENS

URETHRA

PENIS

NERVOUS SYSTEM



BRAIN

NERVES

SPINAL CORD