El gust: la llengua

Membrana pituïtària

Fibres nervioses gustatives

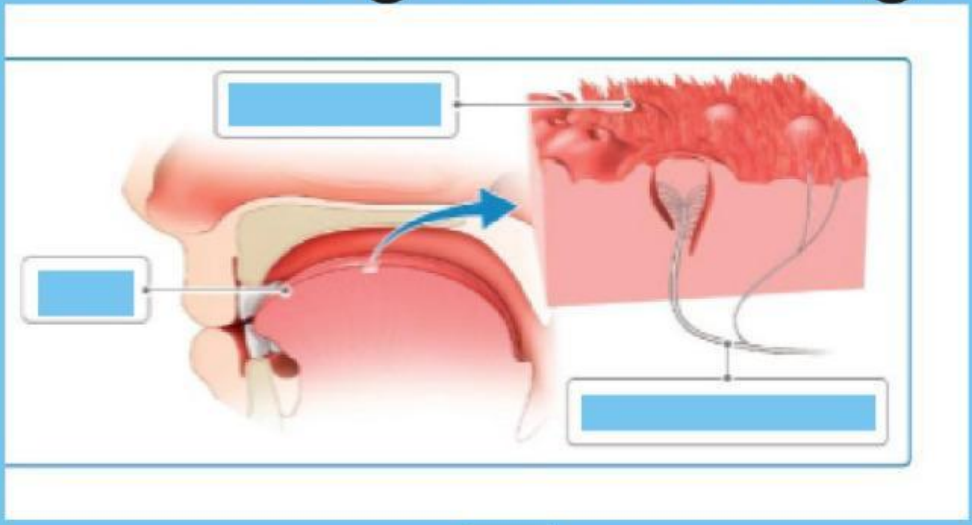

Dermis

L'olfacte: el nas

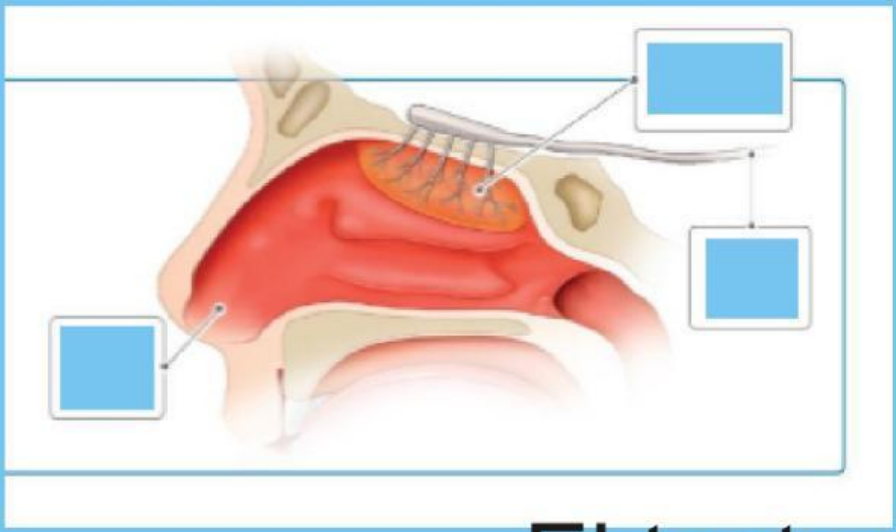

Llengua

Pèl

Múscul

Terminacions nervioses

Nervi olfactiu

Glàndula sudorípara

El tacte: la pell

Papil·les gustatives

Fosses nasals

Epidermis

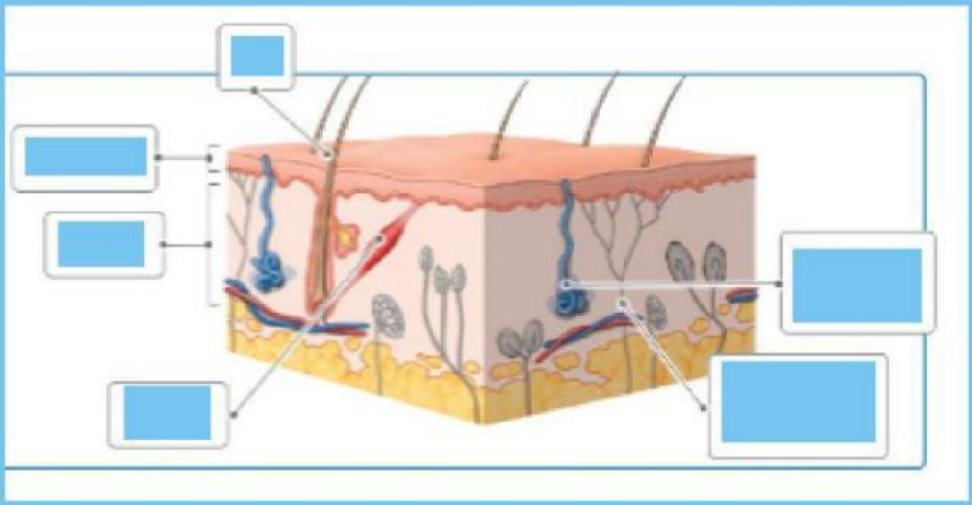

LIVEWORKSHEETS