Anatomia della mano
n.1

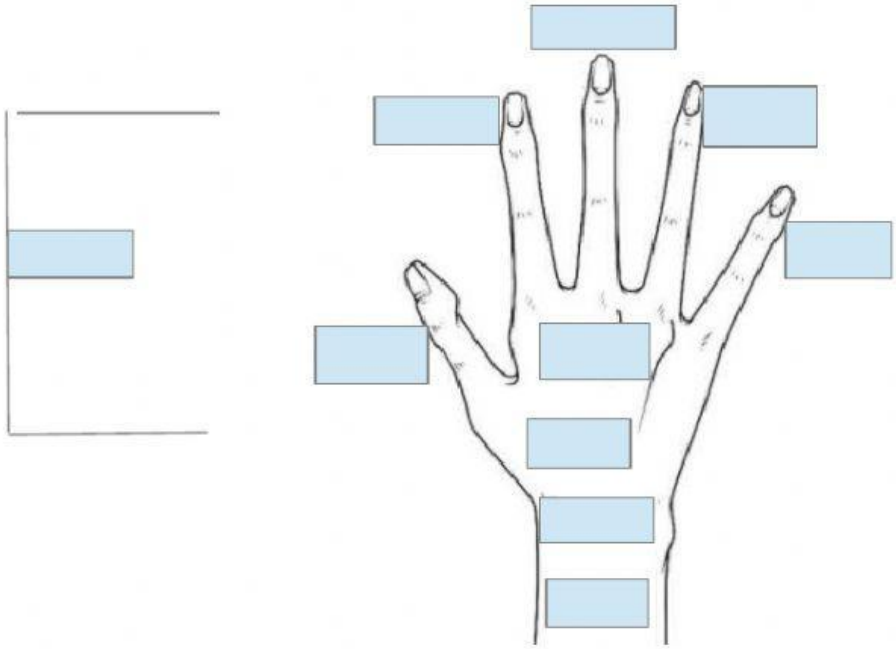

Falangi	Pollice	Medio	Indice	Anulare
Mignolo	Carpo	Metacarpo	Dorso	Polso