

NAMA :

KELAS :

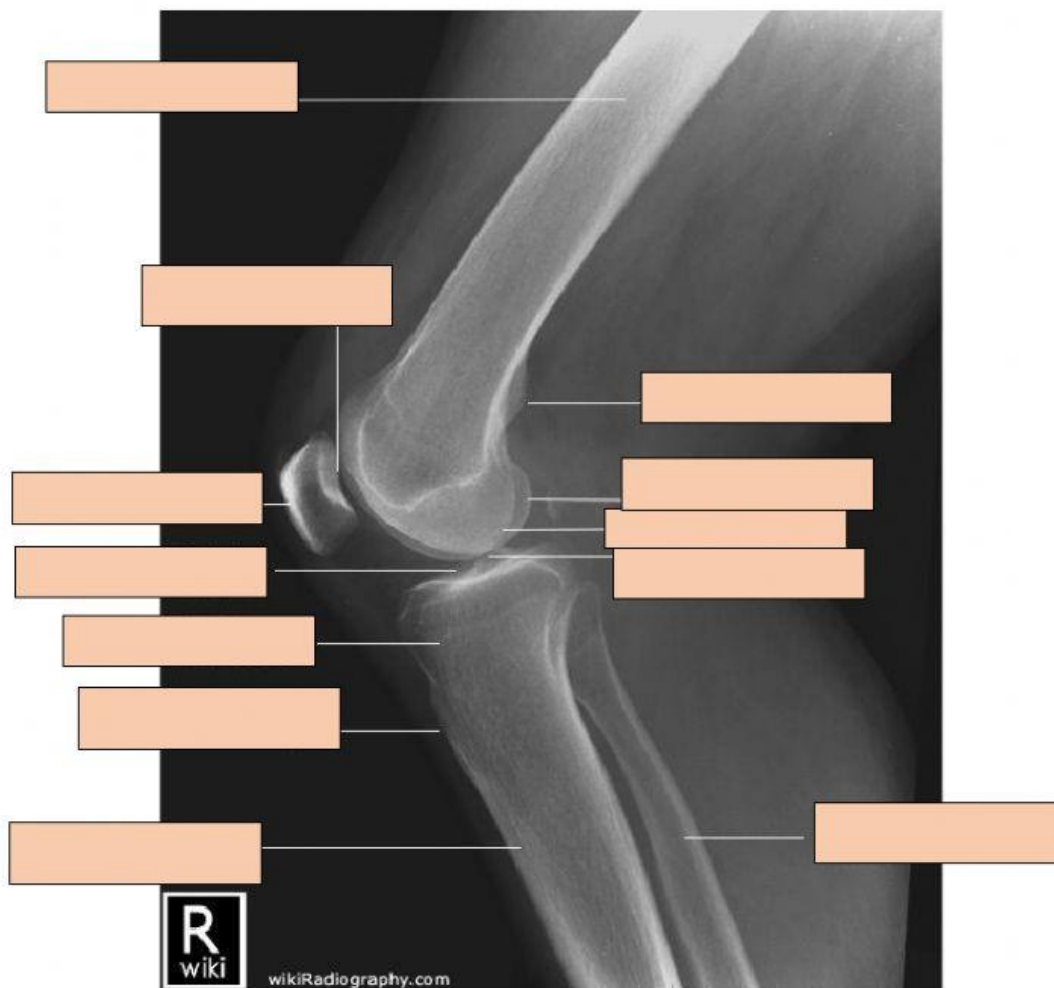
TANGGAL :

LATIHAN UPPER DAN LOWER EXTREMITY

Tuliskan jawaban yang tepat sesuai dengan pilihan jawaban yang tersedia di dalam kotak

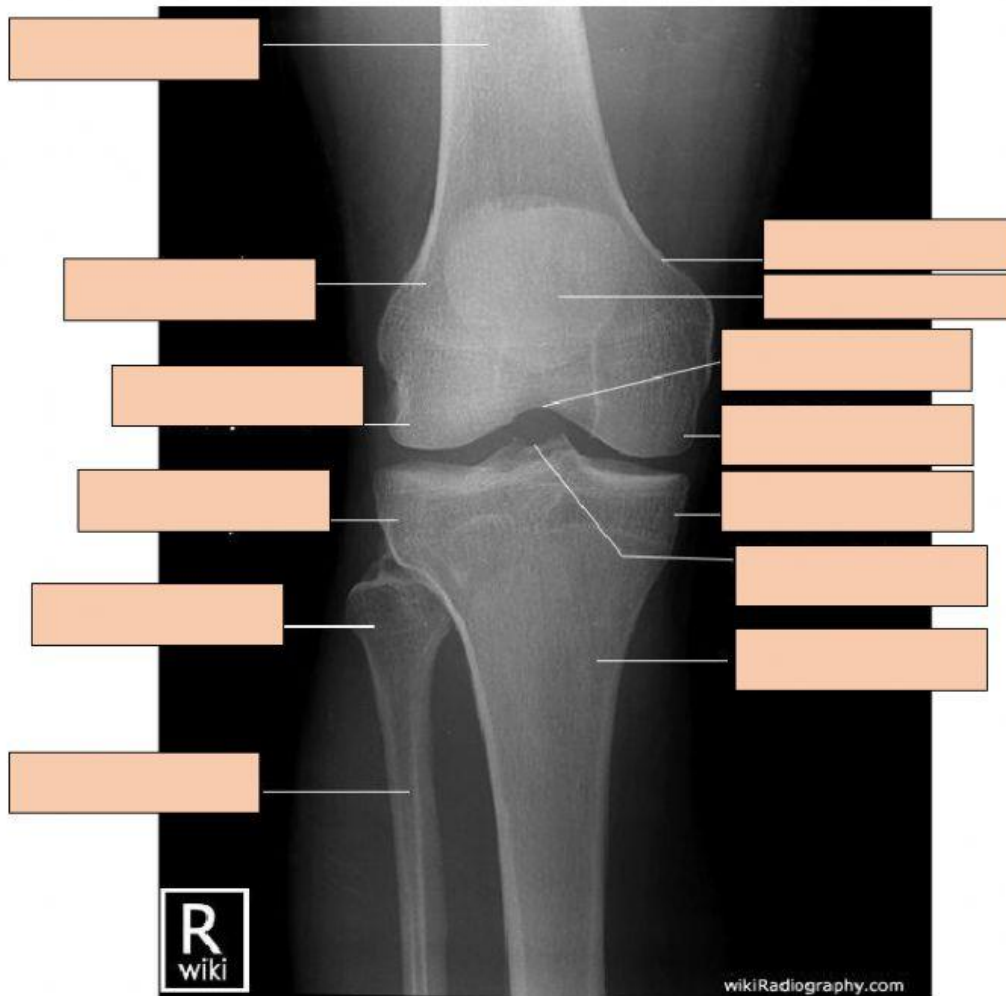
**NOMOR 1.**

tibial plateau – tibial tuberosity – fibula – adductor tubercle – femur –  
 permukaan articular patella – lateral condyle – medial condyle –  
 patella – tibial condyle – intercondylar tubercle - tibia



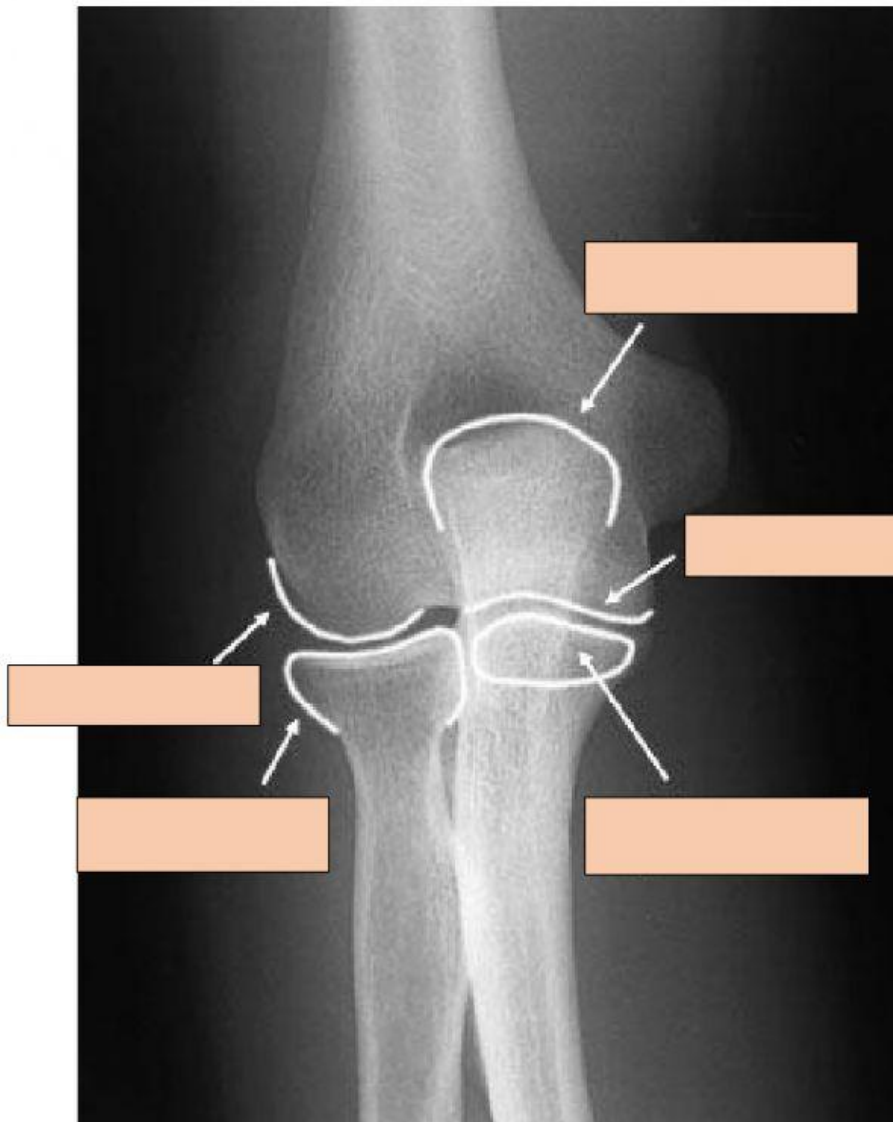
**NOMOR 2.**

tibia – femur – medial epicondyle -intercondylar eminence – head of fibula – lateral epicondyle – intercondylar notch – lateral femoral condyle – lateral tibial condyle – medial tibial condyle – patella - medial femoral condyle



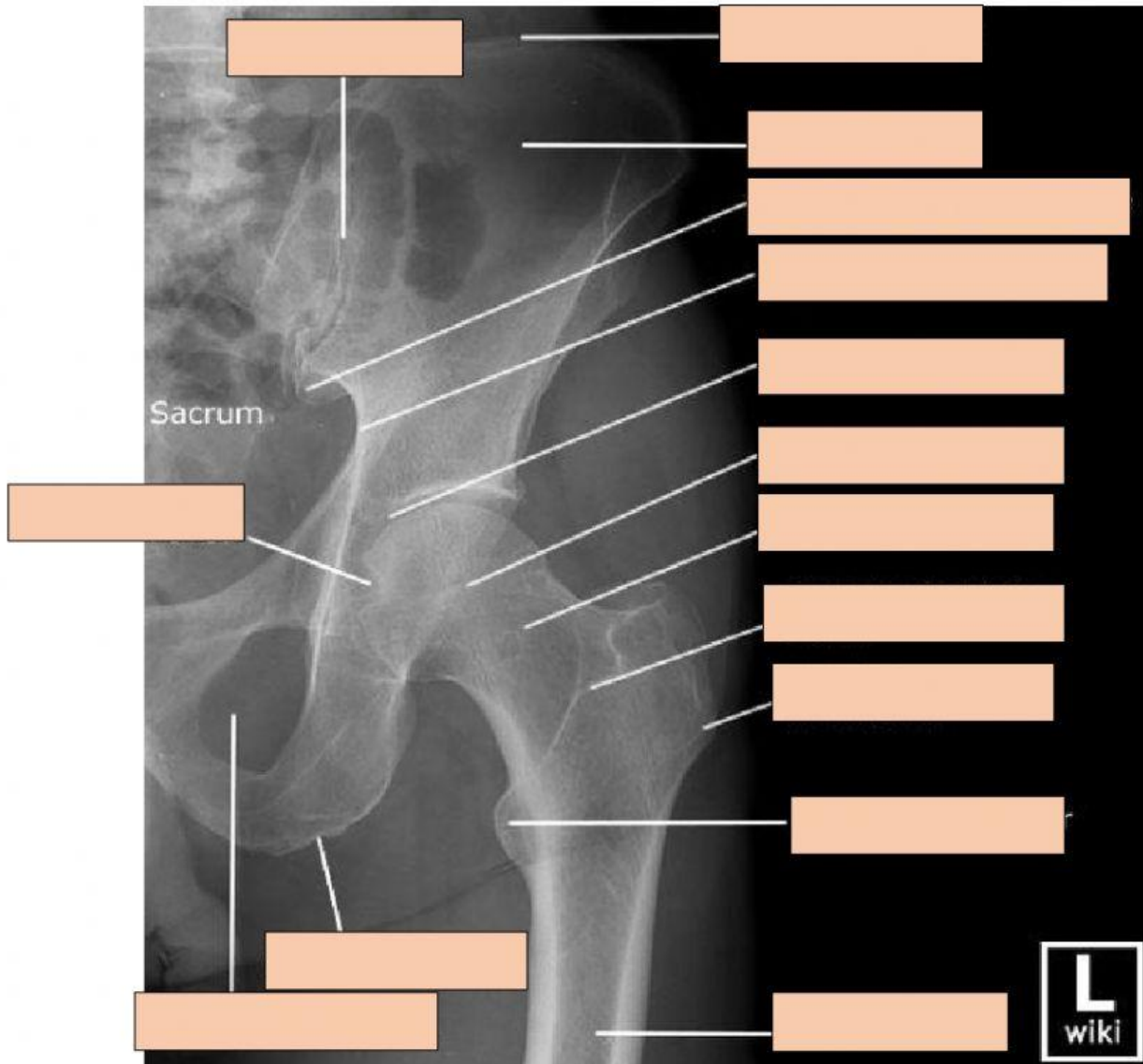
**NOMOR 3.**

prosessus olecranon - prosessus coronoid – trochlea – radial head -  
capitulum



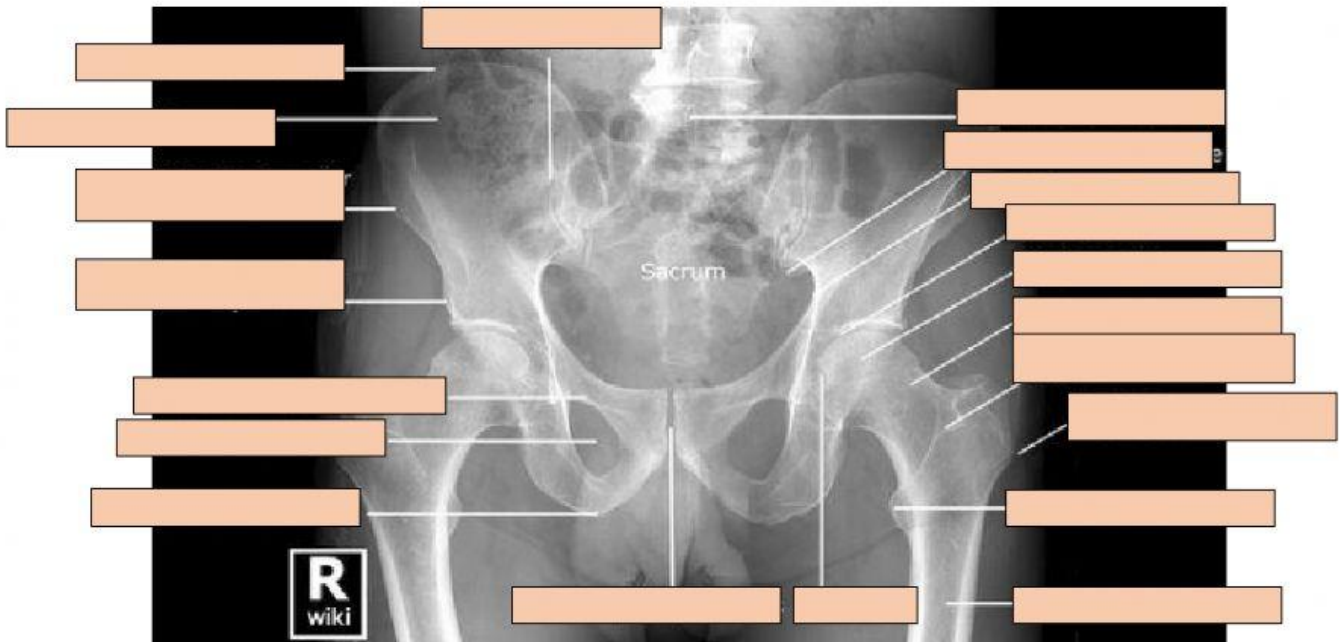
**NOMOR 4.**

Trochanter mayor – trochanter minor – femur – foramen obturatorium – fovea – ischial tuberosity – acetabulum – femoral head – femoral neck – intertrochanteric crest – ilium – crest of ilium – sacroiliac joint – sacrum – posterior inferior spine - greater sciatic notch



**NOMOR 5.**

symphysis pubis – fovea – femur – ilium – crest of ilium – sacroiliac joint –  
trochanter minor – foramen obturatorium – trochanter mayor – vertebra lumbal –  
acetabulum – femoral neck – spina iliac anterior inferior - spina iliac anterior  
superior – ramus pubis superior – ischial tuberosity – femoral head –  
intertrochanteric crest – spine inferior posterior



KODE: anrad/upper-lower-externity/1/nb/2020