# Schichten der Epidermis

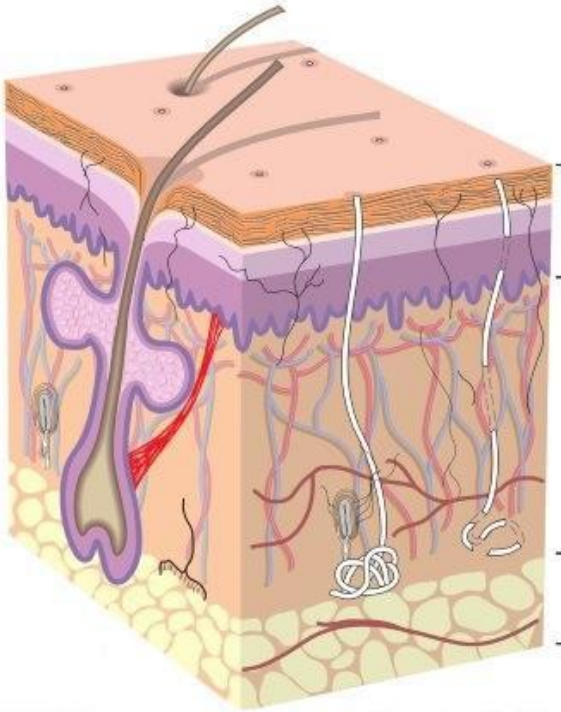

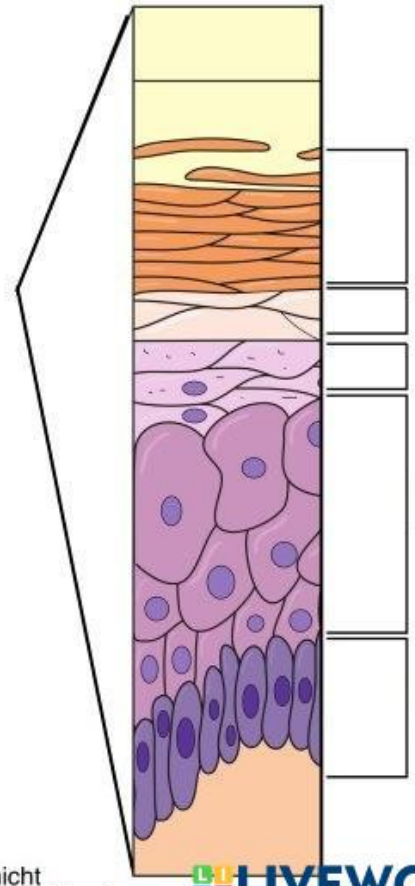

Epidermis (Oberhaut)

Basalzellschicht (**Stratum basale**)

Hornzellschicht (**Stratum corneum**)

Dermis (Lederhaut)

Subcutis (Unterhaut)

Stachelzellschicht (**Stratum spinosum**)

Körnerschicht (**Stratum granulosum**)

Glanzschicht (**Stratum lucidum**)

LIVEWORKSHEETS