

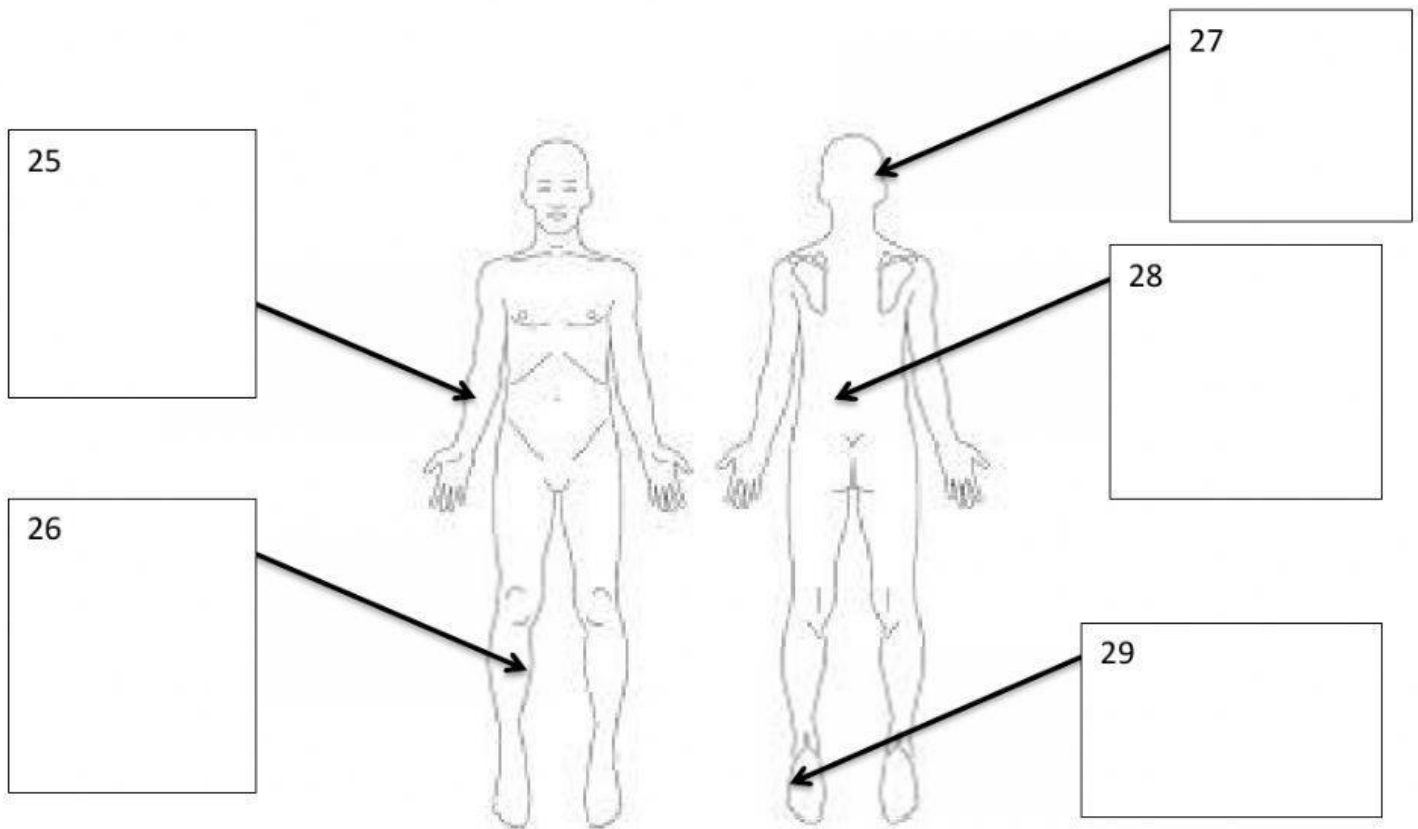
**A. Matching: Match the directional term with its description.**

- |                      |   |
|----------------------|---|
| 1. _____ Medial      | A. Towards the front of the body; ventral.            |
| 2. _____ Lateral     | B. Away from the surface; underneath.                 |
| 3. _____ Inferior    | C. Closer to the trunk, in reference to an extremity. |
| 4. _____ Superior    | D. Toward the midline.                                |
| 5. _____ Proximal    | E. Toward the bottom.                                 |
| 6. _____ Distal      | F. Close to the surface.                              |
| 7. _____ Superficial | G. Toward the back of the body.                       |
| 8. _____ Deep        | H. Away from the midline of the body.                 |
| 9. _____ Anterior    | I. Toward the head.                                   |
| 10. _____ Posterior  | J. Referencing the extremity, farther from the trunk. |

**B. Fill-in-the-Blank: Use the most appropriate directional term(s) to complete the sentence. You may need to have your regional terminology as a reference!**

11. The brachium is \_\_\_\_\_ to the patella.
12. The occiput is \_\_\_\_\_ to the nose.
13. The popliteal region is \_\_\_\_\_ to the femur.
14. The umbilicus is \_\_\_\_\_ to the vertebral region.
15. The humerus is \_\_\_\_\_ to the sternal region.
16. The tarsals are \_\_\_\_\_ to the patella.
17. The lumbar spine is \_\_\_\_\_ to the thoracic spine.
18. The buccal region is \_\_\_\_\_ to the nose.
19. The skin is \_\_\_\_\_ to muscle.
20. The eyes are \_\_\_\_\_ to the oral region.
21. The visceral pleura is \_\_\_\_\_ to the parietal pleura.
22. The fingers are \_\_\_\_\_ to the antecubital region.
23. The coxal region is \_\_\_\_\_ to the abdomen.
24. The sural region is \_\_\_\_\_ to the gluteal region.

**C. Where is the Wound? Identify the Location! On each of the following diagrams, there are numbers that indicate a wound. Describe the location of each number using directional (and regional) terms!**



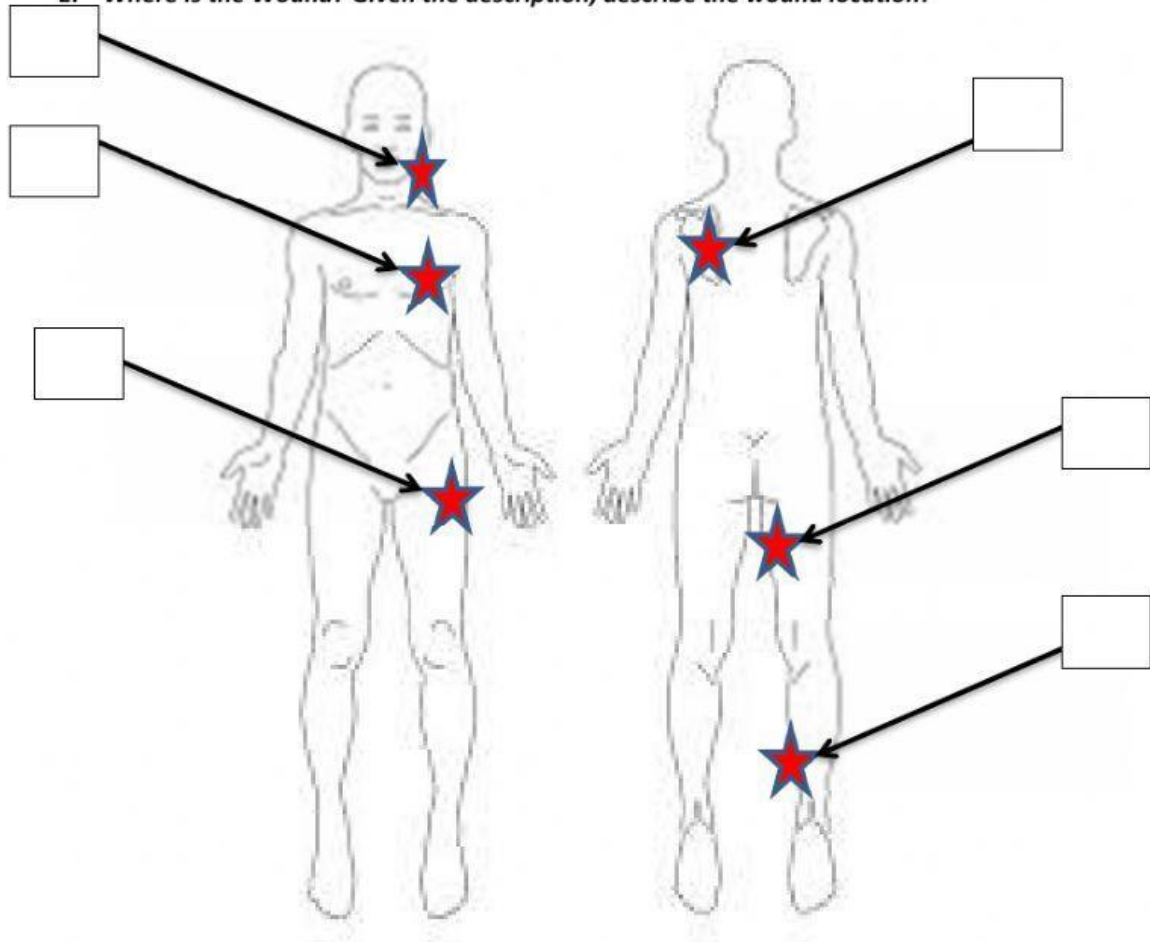
**D. Planes: Describe the regions that are divided by each plane, using directional terms.**

30. Transverse: \_\_\_\_\_

31. Sagittal: \_\_\_\_\_

32. Frontal: \_\_\_\_\_

E. Where is the Wound? Given the description, describe the wound location!



33. Draw an \* and the #33 to designate a wound on the right medial, posterior, distal lower extremity.

34. Draw an \* and the #34 on the left anterior, lateral, superior trunk.

35. Draw an \* and the #35 on the left lateral, posterior, superior trunk.

36. Draw an \* and the #36 on the right proximal, medial, superior, posterior lower extremity.

37. Draw an \* and the #37 on the left, anterior, inferior face.

38. Draw an \* and the #38 on the proximal, left, anterior lateral lower extremity.