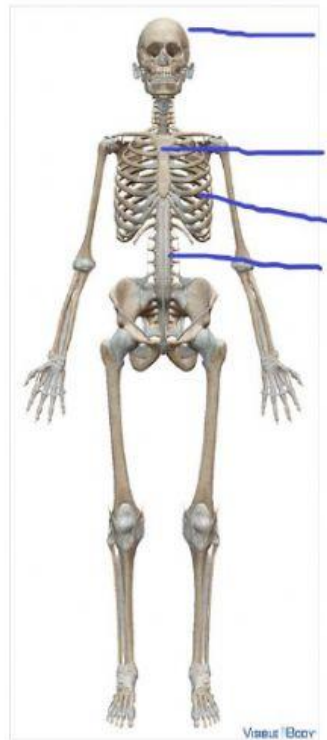


NAME :

SKELETAL SYSTEM



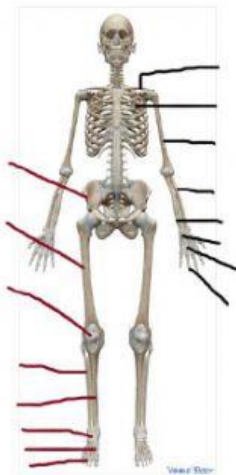
VERTEBRAL COLUMN

SKULL

STERNUM

RIBS

THIS IS THE (AXIAL / APPENDICULAR) SYSTEM



This is the (axial / appendicular) system .